

# Laser-assisted immediate implantation at infected site

**Authors**\_Drs Avi Reyhanian, Natan Fuhrman, Israel & Costas Ioannou, Cyprus

## Abstract

Osseointegration of dental implants has become a routinely recommended procedure in the clinical practice of dentistry.<sup>1-4</sup> Over the years, patients have begun to demand a shortened treatment time and that treatment be done in one visit, to the extent possible. This clinical case study will discuss and demonstrate the correct use of the Er:YAG laser (2,940nm) in immediate placement of implants (in one visit) at the infected site: extraction, degranulation, decontamination, placing the implant, and treating the bone defect (guided-bone regeneration—GBR).

This technique using the Er:YAG laser presents several advantages compared with conventional treatment methods, and there are minimal post-operative complications coupled with a high success rate.

### *Introduction of the clinical case*

A 21-year-old soldier presented to the clinic with the chief complaint of mobility of tooth #11. There was no medical history. He had undergone trauma to the tooth a year before, which had been untreated. Clinical examination revealed mobility grade 3+ at tooth #11 with fistula and a change of

**Fig. 1**\_Mobility and fistula of tooth #11.

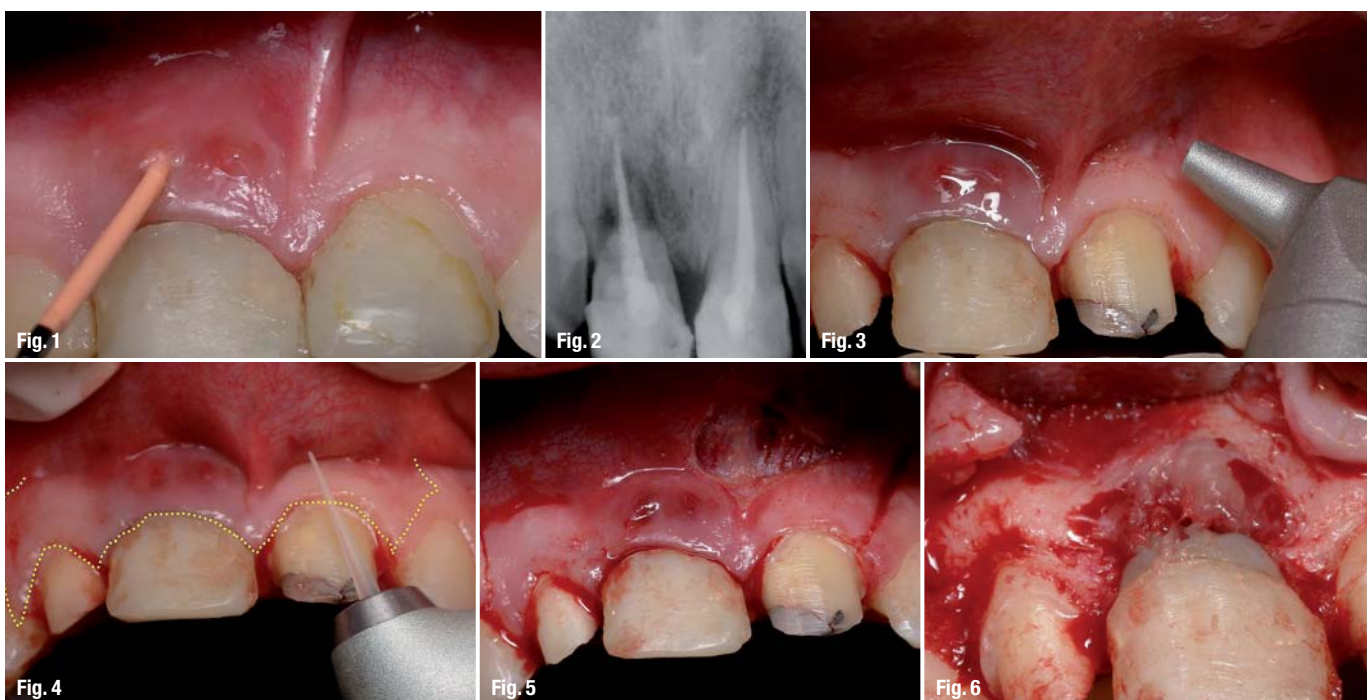
**Fig. 2**\_X-ray image of teeth #11 and 21.

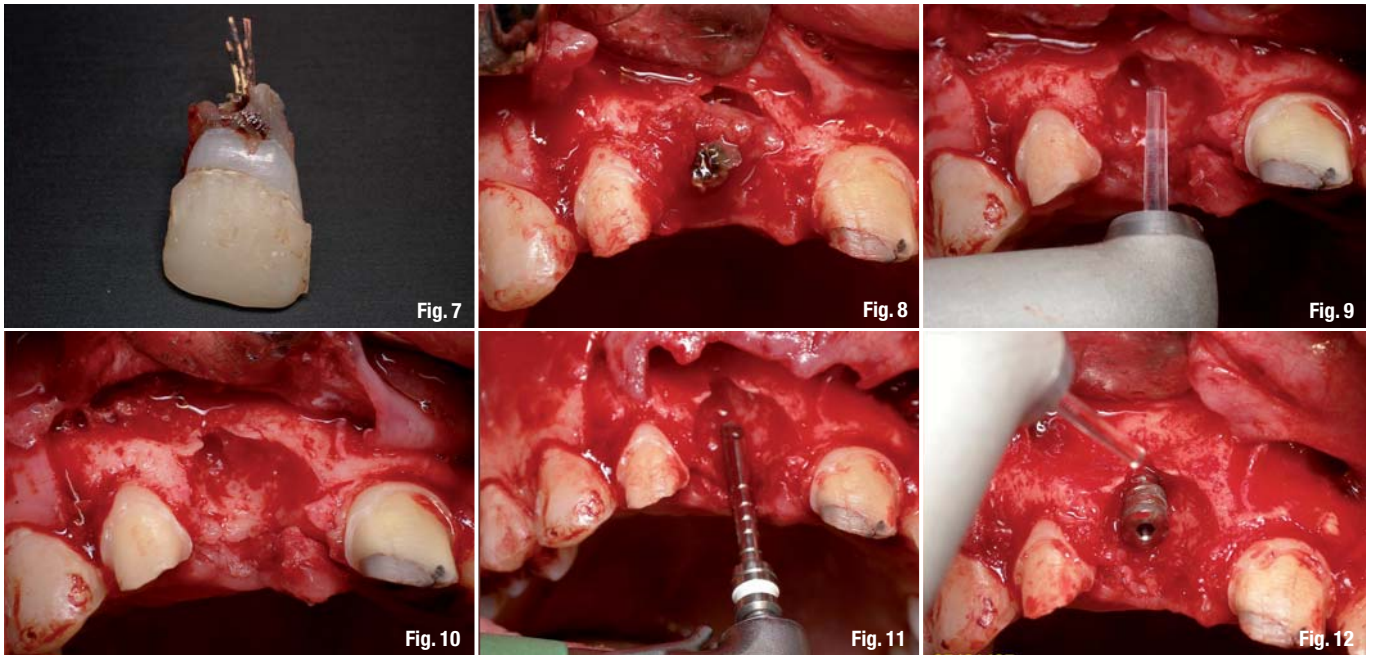
**Fig. 3**\_The CO<sub>2</sub> laser used for the frenectomy.

**Fig. 4**\_The Er:YAG laser used for incision.

**Fig. 5**\_The intrasulcular and vertical incisions and the frenectomy.

**Fig. 6**\_Lifting the flap.





colour of tooth #21. A periodontal probe indicated a depth pocket of 9mm and bleeding on probing. Radiographs revealed horizontal and vertical bone loss due to trauma around teeth #11 and 21 with root canal (Figs. 1 & 2).

Implant indications for laser treatment:

- \_ frenectomy using the CO<sub>2</sub> laser;
- \_ incision using the Er:YAG laser;
- \_ lifting a flap.

Simultaneous (combined) approach:

- \_ extraction;
- \_ ablation of granulation tissue using the Er:YAG laser;
- \_ insertion of immediate implant using the Er:YAG laser—lasing just the cortical bone;
- \_ GBR using the Er:YAG laser;
- \_ primary closure.

Treatment alternatives:

- \_ Using conventional treatment
  - scalpel
  - surgical bur
  - high-speed rotary instruments
  - GBR
  - sutures
- \_ Multiple post-operative appointments: staged approach
- \_ Placement of the fixture after healing.

*Diagnosis and treatment plan*

Severe periodontitis with massive bone loss around tooth #11 was diagnosed. The treatment plan entailed lifting a flap, extraction of the tooth

and immediate placement of a submerged implant, using a CO<sub>2</sub> laser for the frenectomy, then using an Er:YAG laser for incision, ablation of granulation tissue, bone remodelling and shaping decortication for GBR. Uncovering of the submerged implant with an Er:YAG laser was to be done a year later.

*Rational for treatment*

The pulsed Er:YAG laser can cut and ablate tissue with excellent surgical precision without excessive heat or thermal injury. Healing time is shortened when compared with a scalpel or hand instruments. Using a CO<sub>2</sub> laser for a frenectomy results in no bleeding, no pain post-operatively, and a reduced healing time compared with conventional methods.

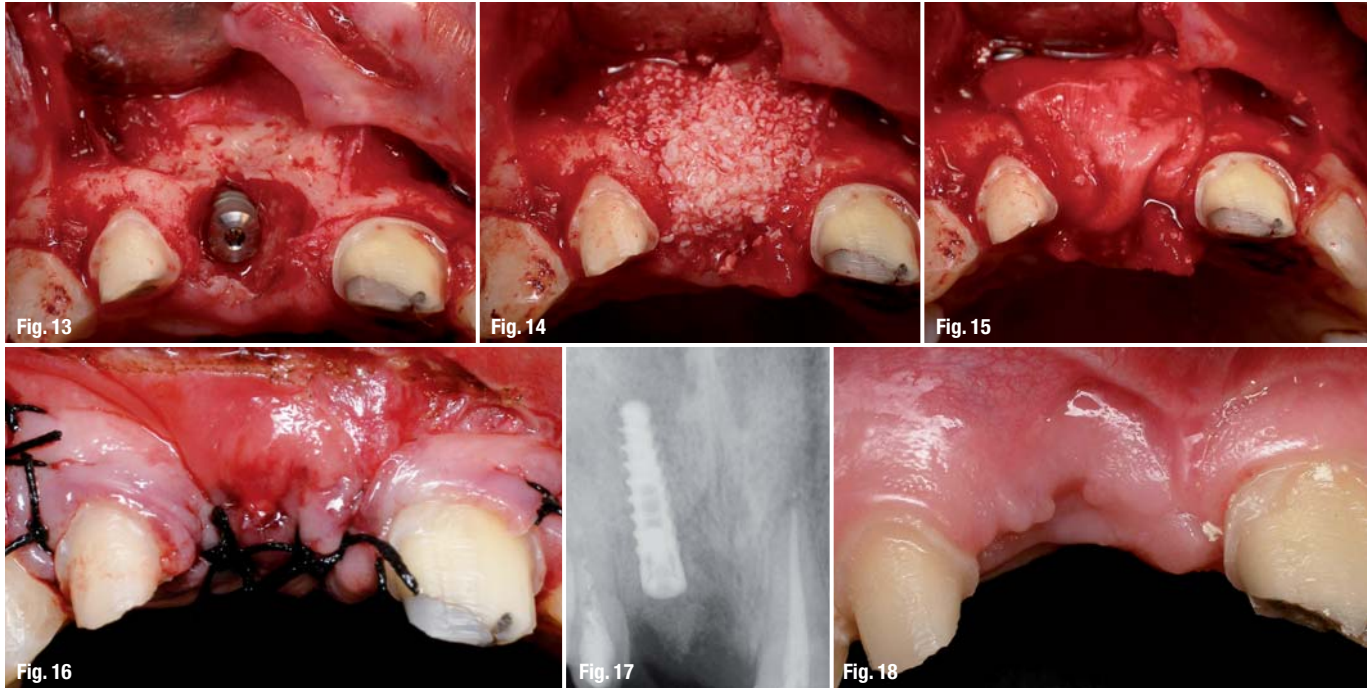
*Indications/contra-indications and alternative treatment*

There were no contra-indications for use of the laser on this patient. Care must be taken to set proper parameters and use a proper technique, so that both hard and soft tissues are not ablated when only one of the tissues is being targeted. Maximum water spray cooling must be used with the Er:YAG laser to avoid thermal damage.

*Clinical technique, laser wavelength and laser operating parameters*

The lasers selected for the frenectomy were a CO<sub>2</sub> laser (Aqualite, Lumenis Dental; 10,600nm, 6W, SP, non-contact), a free-running, pulsed Er:YAG laser (LiteTouch, Syneron Medical Ltd; 2,940nm, repetition rate of 17–10Hz, 400–700mJ). The tips

**Fig. 7**\_The extracted tooth.  
**Fig. 8**\_The bone defect.  
**Fig. 9**\_The Er:YAG laser ablates the granulation tissue.  
**Fig. 10**\_The bone defect after ablation and marking the location of the implant with the Er:YAG laser.  
**Fig. 11**\_The pilot hole.  
**Fig. 12**\_Decortication with the Er:YAG laser.



**Fig. 13** \_Immediately after decortication.  
**Fig. 14** \_Xenograft using Bio-Oss for GBR.  
**Fig. 15** \_Resorbable membrane.  
**Fig. 16** \_Primary closure.  
**Fig. 17** \_X-ray image immediately post-op.  
**Fig. 18** \_Three months post-op.

used were 200 $\mu$  and 1,300 $\mu$  sapphire tips. The laser selected for uncovering the submerged implant was an Er:YAG laser (LiteTouch) with a 200 $\mu$  sapphire tip and a power setting of 300 mJ/25 Hz.

*Treatment sequence*

Verbal consent was obtained from the patient and his parents after explaining the advantages of laser treatment compared with conventional surgical techniques.

Local anaesthetic was first given to the patient. The frenectomy was then performed with the CO<sub>2</sub> laser set in non-contact mode and to 6 WSP (Fig. 3).<sup>5-7</sup>

Er:YAG lasers can be used to make an incision for flap lifting, such as crestal, intrasulcular or vertical release incisions, and produce a wet incision (some bleeding) as opposed to the dry incision (no bleeding) produced by the CO<sub>2</sub> laser.<sup>8-11</sup>

The Er:YAG laser with a 200 $\mu$  sapphire tip and set in contact mode was used to perform intrasulcular incision and two vertical incisions (Figs. 4 & 5). A full-thickness flap was lifted (Fig. 6) and tooth # 11 was extracted (Fig. 7).

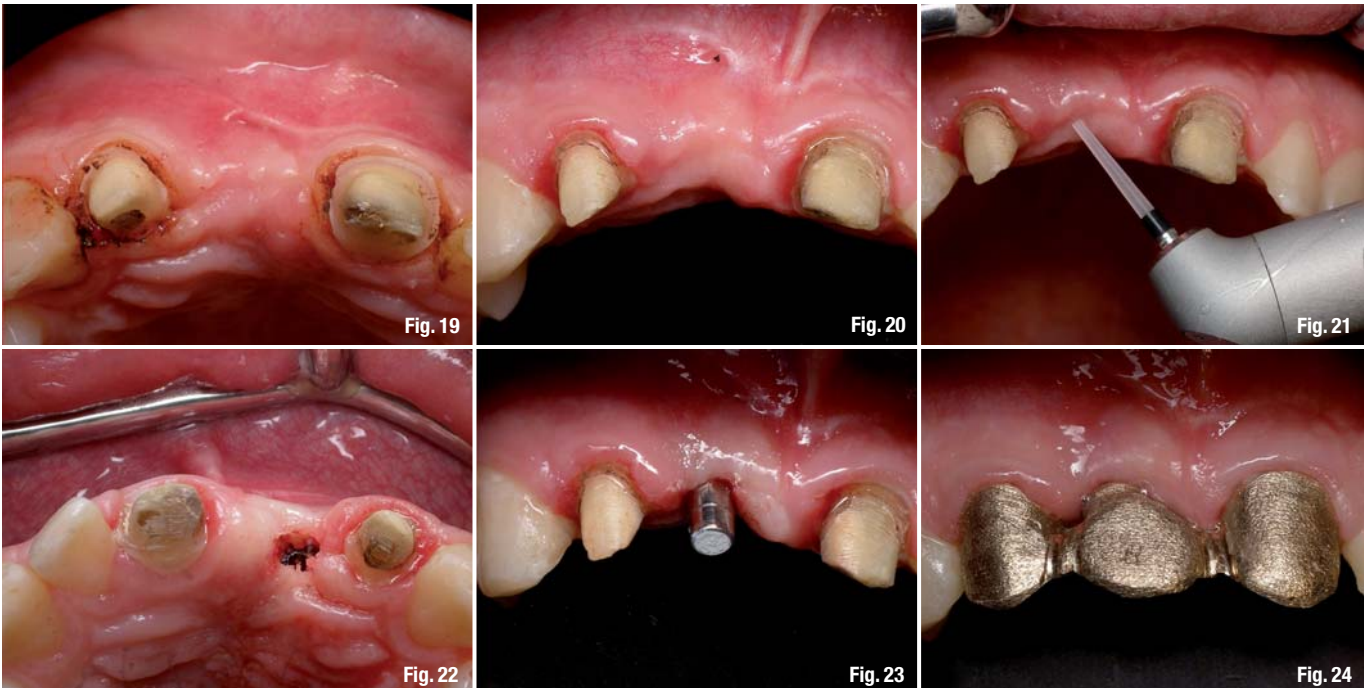Vaporisation of granulation tissue (if any exists) after lifting a flap can be done efficiently with the Er:YAG laser, with a lower risk of overheating the bone than with the current diode or CO<sub>2</sub> lasers.<sup>11,17,14</sup> There is no need for any hand instruments. Results from both controlled clinical and basic studies have pointed to the high potential of the Er:YAG laser. Its

excellent ability to ablate soft tissue effectively without producing major thermal side-effects to adjacent tissue has been demonstrated in numerous studies.<sup>12-15</sup>

Granulation tissue was ablated with the Er:YAG laser with a 1,300 $\mu$  tip in non-contact mode and with a power setting of 600 mJ/12 pps (Figs. 8 & 9). Detoxification of the infected site was done by lasering directly on the bone, using a low-energy setting. In this way, the target tissue was disinfected without injuring the bone. The laser is bactericidal.<sup>15,16</sup> The necrotic bone was ablated using the Er:YAG laser with a 1,300 $\mu$  sapphire tip in non-contact mode and with a power setting of 350 mJ/20 pps.<sup>8,10,17,18</sup>

The placement site for the implant was marked with the Er:YAG laser (Fig. 10), and the entire length of the implant was prepared using rotary instruments (Fig. 11). The laser does not replace the pilot drill; it is used to create a pilot hole for the drill. The preparation for the entire length of the implant should not be lasered with the laser.

An implant with a length of 13 mm and diameter of 3.75 mm (MIS Implants Technologies Ltd) was placed manually (Fig. 12). The bone defect required GBR. Decortication was performed with the Er:YAG laser with a 1,300 $\mu$  sapphire tip in non-contact mode and with a power setting of 400 mJ/12 pps (Figs. 12 & 13). The bone defect around the implant was filled with Bio-Oss bone substitute (Geistlich Biomaterials) and covered with Bio-Gide (Geistlich Biomaterials), an absorbent, bilayer membrane



(Figs. 14 & 15). Sutures were applied and primary closure was achieved (Fig. 16). An X-ray was taken to confirm the placement of the implants (Fig. 17).

### **Biological rationale for immediate implantation**

- Simplified procedure that reduces the surgical stages;
- conservation of bone volume surrounding natural tooth;
- combination of post-extraction healing phase with osseointegration;
- maximum stimulation of natural healing processes;
- shortened healing phase and rehabilitation time;
- positive psychological effect on the patient.

### **Post-operative assessment**

The patient was prescribed Clindamycin (150 mg x 50 tabs) to avoid infection. He was also given Motrin (800 mg x 15 tabs) for pain. Instructions were given to rinse with a 0.2% chlorhexidine mouthwash, starting the next day for two weeks (three times a day). The patient returned for his first follow-up the next day with a moderate swelling and pain. The flap was closed. At ten days, the patient returned for the stitches to be removed and there were no signs of swelling haematoma or pain. After one month, the soft tissue had healed. A three-month evaluation of the area showed complete healing and no complications (Fig. 18). The soft issue had healed over the bone and there were no bony projections observed under the soft tissue. The prognosis was excellent.

### **Complications**

The patient had no complications related to laser treatment either during or after laser therapy. There was no soft or hard tissue damage.

### **Follow-up and long-term results**

The patient was assessed once a week in the first month, at six weeks, three months and six months after the start of the treatment. At the fifth-month supportive periodontal therapy appointment, the patient had excellent healing and had improved tissue colour, contour and consistency (Fig. 19).

A year post-treatment the submerged implant was uncovered with the Er:YAG laser with an 800µ sapphire tip in non-contact mode and with a power setting of 400 mJ/25 pps (Figs. 20–23). Five months after this, the rehabilitation was completed: three crowns on teeth #12, 11 (eight implants) and 21 (Figs. 24 & 25).

This case was followed-up for three years and two months (Figs. 26 & 27). An X-ray image shows a small absorption of bone around the neck of the implant.

### **Conclusion**

We conclude that using the 2,940 nm wavelength laser for these procedures offers many advantages compared with conventional methods, such as the reduction of patient discomfort, enhancement of the surgical site and reduced treatment time.<sup>21</sup> This

**Fig. 19** Five months post-op, showing complete closure.

**Fig. 20** A year post-op.

**Fig. 21** Using the Er:YAG laser to uncover the submerged implant.

**Fig. 22** The uncovered implant.

**Fig. 23** The abutment.

**Fig. 24** The alloy part of the rehabilitation – porcelain-fused-to-gold crowns.

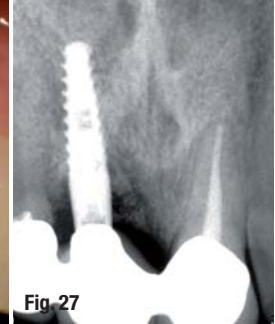
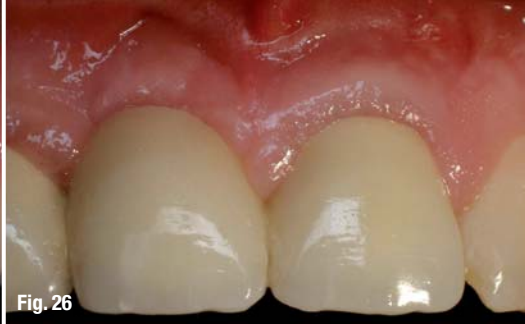
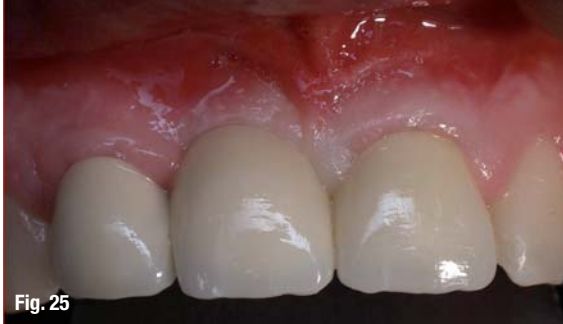
Fig. 25

Fig. 26

Fig. 27

**Fig. 25** Final result a year and five months post-op.

**Fig. 26** Three years and two months post-op.

**Fig. 27** X-ray image three years and two months post-op.

wavelength can be employed for the purpose of the decontamination of infected sites and it has been shown to be effective and safe.<sup>12,19,20</sup> In addition, post-operative effects such as pain and swelling are less pronounced. This laser has become an invaluable tool for many procedures by simplifying treatment and offering patients faster, less stressful oral therapy with enhanced outcomes.

This case demonstrates that the Er:YAG laser is a very valuable tool that shows promise and safety as an effective new technical modality for implant therapy. However, further clinical and basic investigations are required to establish the clinical effectiveness and safety of the Er:YAG laser in implant site preparation.

### References

1. Adell R, Lekholm U, Rockler B, Brånemark PI, "A 15-Year Study of Osseointegrated Implants in the Treatment of the Edentulous Jaw". *Int J Oral Surg.* 1981 Dec;10(6):387-416.
2. Albrektsson T, "A Multicenter report on Osseointegrated Oral Implants". *J Prosthet Dent.* 1988 Jul;60(1):75-84.
3. Buser D, Mericske-Stern R, Dula K, Lang Nova Pulse, "Clinical Experience with One-Stage, Non-Submerged Dental Implants". *Adv Dent Res.* 1999 Jun;13:153-61.
4. Olsson M, Friberg B, Nilson H, Kultje C, "Mkl – a Modified Self-Tapping Branemark Implant: 3-Year Results of a Controlled Prospective Pilot Study". *Int J Oral Maxillofac Implants.* 1995 Mar-Apr;10(2):243.
5. Shetty K, Trajtenberg C, Patel C, Streckfus C. "Maxillary frenectomy using a carbon dioxide laser in a pediatric patient: a case report". *Gen Dent.* 2008 Jan-Feb;56(1):60-3.
6. Haytac MC, Ozcelik O. "Evaluation of patient perceptions after frenectomy operations: a comparison of carbon dioxide laser and scalpel techniques". *J Periodontol.* 2006 Nov;77(11):1815-9.
7. Fiorotti RC, Bertolini MM, Nicola JH, Nicola EM. "Early lingual frenectomy assisted by CO<sub>2</sub> laser helps prevention and treatment of functional alterations caused by ankyloglossia". *Int J Orofacial Myology.* 2004 Nov;30:64-71.
8. Ishikawa I, Aoki A, Takasaki AA, "Potential Applications of Er:YAG Laser in Periodontics" *J Perio Res.* 2004 Aug;39(4): 275-85.
9. Watanabe H, Ishikawa I, Suzuki M, Hasegawa K, "Clinical Assessments of the Erbium:YAG Laser for Soft Tissue Surgery and Scaling", *J Clin Laser Med Surg.* 1996 Apr,14(2):67-75.
10. Ishikawa I, Sasaki KM, Aoki A., Watanabe H, "Effects of Er:YAG Laser on Periodontal Therapy", *J Int Acad Periodontol.* 2003 Jan;5(1): 23-8.
11. Sasaki KM, Aoki A., Ichinose S, Yoshino T, Yamada S, Ishikawa L, "Scanning Electron Microscopy and Fourier Transformed Infrared Spectroscopy Analysis of Bone Removal Using Er:YAG and CO<sub>2</sub> Lasers", *J Perio.* 2002 Jun; 73(6):643-52.
12. Sasaki KM, Aoki A., Ichinose S, Yoshino T, Yamada S, Ishikawa L, "Scanning Electron Microscopy and Fourier Transformed Infrared Spectroscopy Analysis of Bone Removal Using Er:YAG and CO<sub>2</sub> Lasers", *J Perio.* 2002 Jun; 73(6):643-52.
13. Kreisler M, Al Haj H, d'Hoedt B. "Temperature Changes at the Implant-Bone Interface During Simulated Surface Decontamination with an Er:YAG Laser". *Int J Prosthodont.* 2002 Nov-Dec;15(6):582-7.
14. Schwarz F, Rothamel D, Becker J, "Influence of an Er:YAG Laser on the Surface Structure of Titanium Implants", *Schweiz Monatsschr Zahnmed.* 2003;113(6):660-71.
15. Schwarz F, Bieling K, Sculean A, Herten M, Becker J, "Treatment of Periimplantitis with Laser or Ultrasound. A Review of the Literature". *Schweiz Monatsschr Zahnmed.* 2004; 114(12): 1228-35.
16. Kreisler M, Kohnen W, Marinello C, Gotz H, Duschner H, Jansen B, d'Hoedt B. "Bactericidal Effect of the Er:YAG Laser on Dental Implant Surfaces: An In Vitro Study", *J Periodontol.* 2002 Nov;73(11):1292-8.
17. Kreisler M, Kohnen W, Christoffers AB, Gotz H, Jansen B, Duschner H, d'Hoedt B. "In Vitro Evaluation of the Biocompatibility of Contaminated Implant Surfaces Treated with an Er:YAG Laser and an Air Powder System". *Clin Oral Implants Res.* 2005 Feb;16(1):36-43.

*Editorial note: The whole list of references is available from the publisher.*

_contact	laser
<p><b>Avi Reyhanian, DDS</b> Shaar Haemek Street, Netanya 42292, Israel</p> <p><b>Natan Fuhrman, DDS</b> Institute of Advanced Dental Education, Haifa, Israel</p> <p><b>Costas Ioannou, DDS</b> 35 Ifigenias str 2007, Nicosia, Cyprus</p>	