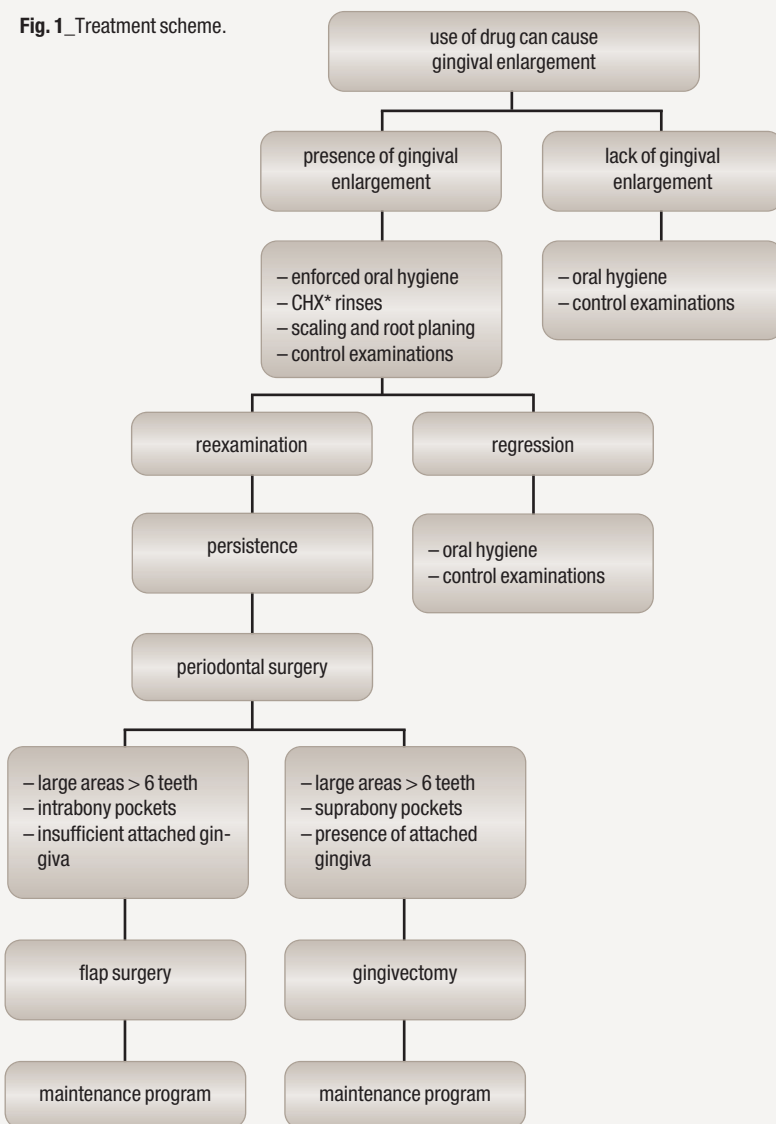


Treatment of drug-induced gingival enlargement with Er:YAG laser

Authors_Dr Blagovesta Yaneva, Professor Georgi Tomov, Bulgaria

Fig. 1_Treatment scheme.

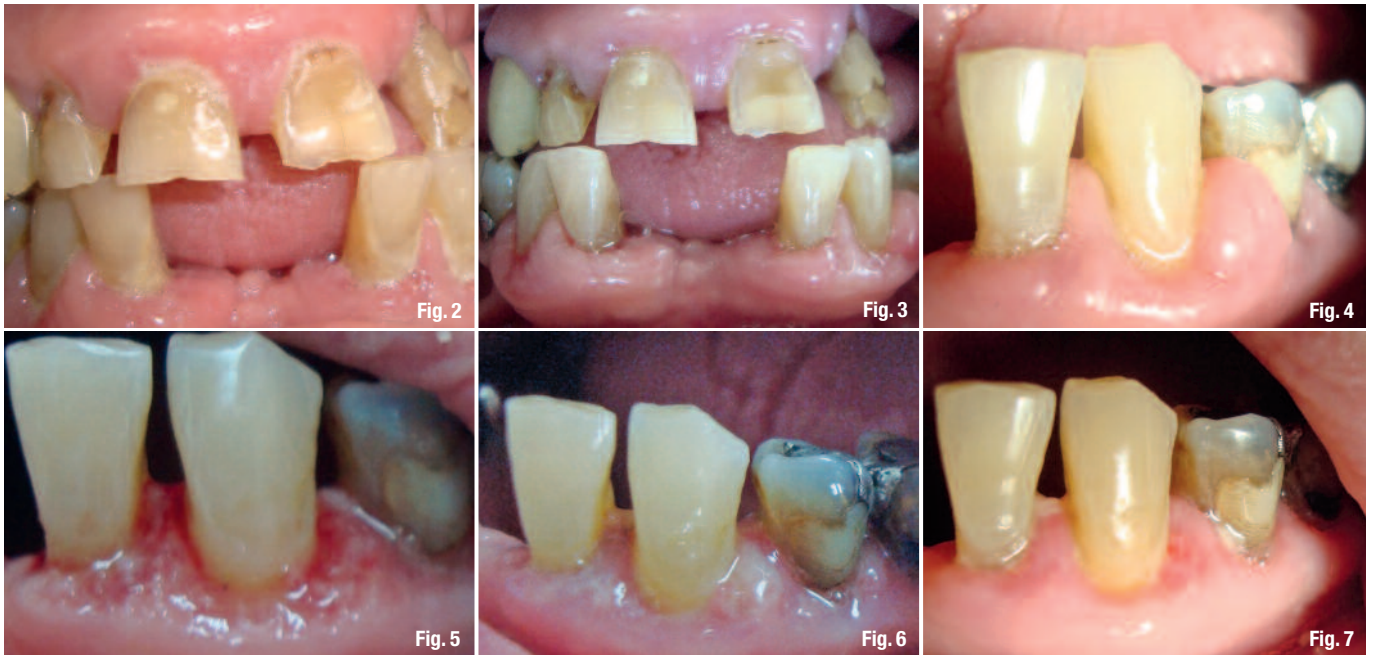

_Introduction

According to the Classification System for Periodontal Diseases and Conditions (1999)¹, drug-induced gingival enlargement belongs to the group of gingival diseases modified by medications which are part of dental plaque-induced gingival diseases. Gingival overgrowth is associated with systemic use of anticonvulsant drugs used for treatment of epilepsy, immunosuppressive drugs used to avoid host rejection of grafted tissues and calcium channel blockers used as antihypertensive drugs. It was first reported by Kimball in 1939 connected to systemic use of phenitoin.² Since then, gingival enlargement has been reported in association of administration of several drugs including cyclosporin³ and different antihypertensive drugs as calcium channel blockers^{4,5}, angiotensine converting enzyme (ACE) inhibitors and β -blockers.⁶

Clinically, gingival enlargement is presented as painless, firm, nodular expansion of interdental papilla. It is a generalised condition, but is more severe in the maxillary and mandibular anterior segments. Gingival enlargement occurs in proximity to the teeth and not in toothless jaw sections. Drug-induced gingival overgrowth can occur in sites with minimal or no plaque, but it interferes with oral hygiene and may often lead to chronic inflammation, which complicates the enlargement. In cases with secondary gingival inflammation, the gingiva is bluish-red in colour, with a lobulated surface and a tendency for bleeding.⁷

Histopathologically this condition is presented by hyperplasia of connective tissue and epithelium. There is acanthosis of the epithelium and deep ep-



ithelial ridges are penetrating into the subepithelial connective tissue.⁸ The connective tissue presents many blood vessels and inflammatory cells. But the target cells in this disease are the fibroblasts and there is proliferation of fibroblasts and increased formation of collagen fibres.

_Treatment modalities for gingival enlargement

The possibility of drug substitution must be discussed with the physician of the patient. Subsequently, a treatment scheme as can be seen in Figure 1 should be considered (adapted from Caranza's Clinical Periodontology).

_Surgical treatment

Surgical intervention is the most frequent management strategy for gingival enlargement caused by drugs.¹⁰ Gingivectomy was firstly introduced by Robicsek in 1884¹¹, but the procedure that is employed today was first described by Goldman in 1951.¹² Following the rules of the procedure, bleed-

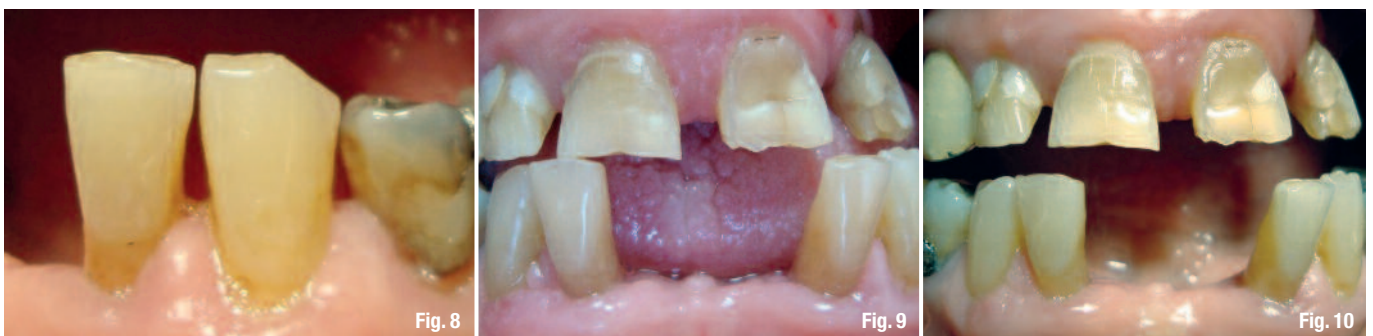ing points are marked first with probes and then the incision is performed apically from these points in coronal direction. The aim of the procedure is to move out the gingival tissue above the bone crest without touching it and without operating on the bone. The standard gingivectomy procedure is performed with scalpels and periodontal knives.

Later, other techniques were reported like tissue removal by using caustic chemicals¹³, gingivectomy by electrosurgery¹⁴, gingivectomy by cryosurgery¹⁵ and gingivectomy by lasers.¹⁶ Different types of laser systems can be used in gingivectomy procedures, like CO₂, diode, Nd:YAG, and Er:YAG. All of them interact in different ways with biological tissues depending on their wavelength.¹⁷

The Er:YAG laser has the best absorption in water molecules and thus is particularly well suited for the treatment of soft tissue such as the gingiva.¹⁸ In contrast to other laser systems, the Er:YAG does not have haemostatic properties, but the healing process after Er:YAG laser surgery is faster, without thermal damage, necrosis etc.¹⁹

Fig. 2_ Initial clinical situation.
Fig. 3_ After professional oral hygiene.
Fig. 4_ Before gingivectomy.
Fig. 5_ Immediately after laser gingivectomy.
Fig. 6_ One day after laser gingivectomy.
Fig. 7_ One week after laser gingivectomy.

Fig. 8_ Six months after laser gingivectomy.
Fig. 9_ Two months later.
Fig. 10_ Six months after laser gingivectomy.



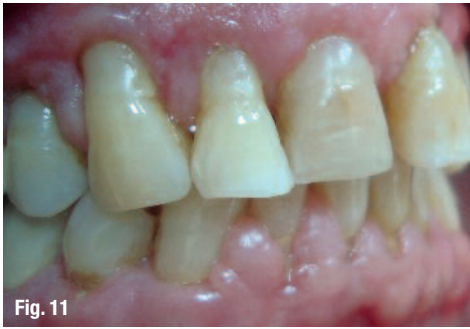

Fig. 11

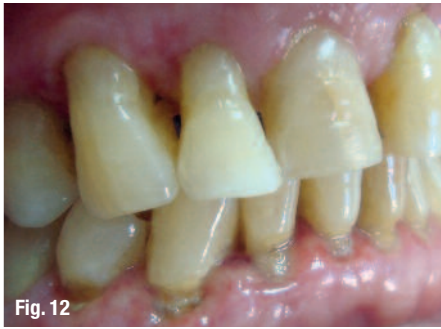

Fig. 12

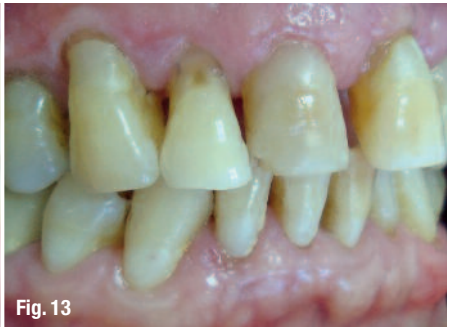

Fig. 13

Fig. 11_Before gingivectomy.

Fig. 12_One week after laser gingivectomy.

Fig. 13_Two months later.

The present report deals with Er:YAG laser surgical treatment of two patients with drug-induced gingival hyperplasia. We assess the treatment results and follow-ups, and investigate the technique to: (a) maximize the precision of the gingival surgery; (b) control postoperative pain after the excision of the hypertrophic gingival tissue; (c) reduce the frequency of relapse in the treated area; and (d) ensure a rapid and compliant postoperative course

Clinical cases

Two patients aged 67 and 73 with complaints of gingival enlargement were referred to the department of Periodontology, Medical University, Plovdiv. Besides gingival hyperplasia, they reported also bleeding gums, halitosis and inability for good oral hygiene. The patients' medical history revealed systemic use of ACE inhibitors (Prestarium 2.5 mg and Co-Enalapril 20 mg/12.5 mg) for antihypertensive treatment.

The intraoral examination revealed generalised, grade II gingival enlargement²⁰ in the anterior segment of the mandible (case I and case II) and the maxilla (case II). There was a high score of debris and calculus index according to Greene-Vermillion index.²¹ The gingiva showed signs of inflammation as redness, bleeding on probing and suppuration. Halitosis was also detected. The measurement of pocket probing depth revealed deep pockets of about 7-8 mm (Figs. 2-14).

Fig. 14_Six months after laser gingivectomy.

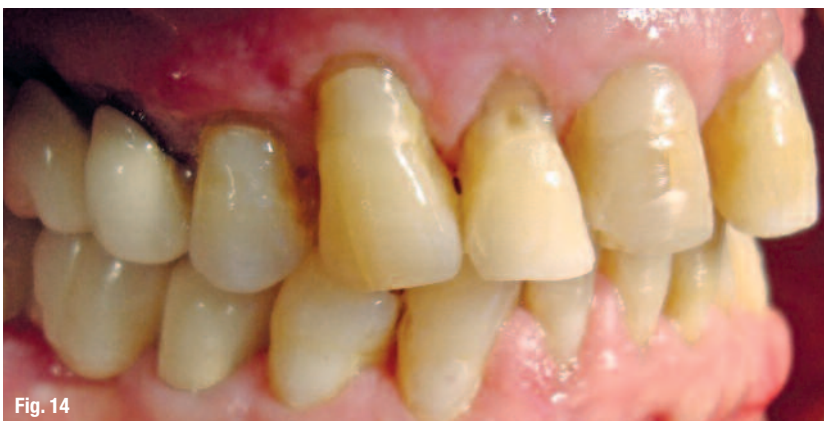

Fig. 14

Management of the patients

Before treatment, a written consent was obtained from the patients and their physicians reported no contraindications for dental procedures. Then, the patients were instructed for intensive oral hygiene including tooth brushing two times a day, rinsing with 0.2% CHX solution and diluted 3% H₂O₂. They were also instructed to use additional oral hygiene tools like interdental brushes and flossing once daily. The initial treatment phase also included ultrasonic cleaning with Piezon Master 400 (EMS, Switzerland). Scaling and root planning with Gracey curettes (Hu Friedy, USA) was performed in one week.

Persistent gingival enlargement was evident after one month and laser gingivectomy was performed in two to four sessions (depending on the treated area) with one week interval between sessions.

Laser gingivectomy

Gingivectomy was performed by Er:YAG laser (LiteTouch™, by Syneron Dental Lasers, Israel) at the following settings: 200 mJ, 18 Hz, 3-4 water spray level. External bevel gingivectomy with tip (0.4 x 17 mm) was performed. Only 10% Lidocaine spray was used for local anaesthesia. An excisional biopsy was taken during gingivectomy, which was fixed in 10% formalin solution and referred for pathological examination (Fig. 15). The level of pain and discomfort during the treatment and healing period was assessed by visual analog scale (VAS).

Results

The Er:YAG laser ablated the soft tissue easily and effectively and the procedure was performed with local anaesthesia only. Although the Er:YAG laser does not possess good haemostatic action, there was no excessive bleeding during and after the gingivectomy. Healing and the patients' subjective assessment were estimated one day, one week and one month after the procedures. The healing process pro-

ceeded without complications and side effects. Patients reported score 0 in the VAS examination, which meant absence of pain and discomfort during and after the laser gingivectomy procedure. Pathological examination confirmed the diagnosis gingival hyperplasia. The tissue samples showed no thermal damage in the incision area. Wound healing was fast and complete within one to two weeks. There were no side effects or complications. Patients were monitored for recurrence during a one-year period.

Discussion

As a first line of treatment for the reduction of gingival overgrowth and anticipating recurrence after surgery, drug withdrawal or substitution was considered. Surgical reduction of the overgrown tissues is frequently necessary to accomplish an aesthetic and functional outcome. The treatment may consist of scalpel gingivectomy or laser gingivectomy. Laser is one of the most promising new technical modalities in periodontal treatment. The Er:YAG laser has a wavelength of 2940 nm, is well absorbed by water and therefore very effective for the surgery of soft tissues, which have a high water content. The advantages of lasers over scalpel surgery are its relatively better haemostatic effect and pronounced bactericidal effect. Also lasers provide good conditions for an accelerated healing process.

However, the practitioners must have excellent knowledge of their specific characteristics and interactions with the tissues to be properly applied in certain manipulations. In the cases presented, the level of thermal damage caused by the Er:YAG laser does not impact the capability of the histological examination of the specimen's peripheral zone. This correlates with the results of the other researchers investigating laser systems effects on soft tissue in the oral cavity.²³

The advantage of the LiteTouch™ Er:YAG laser is a shallower penetration of the laser energy into the tissue (0.05 mm) and the presence of additional water cooling.²³ There are different speculations about the laser thermal effects on soft tissue in the oral cavity. Pathomorphological changes obtained by the CO₂, diode and Nd:YAG lasers are in the zones of moderate and severe thermal damage.²³

This level of modification makes it difficult or even impossible to accurately evaluate cells' changes in the treated areas.²³

These results are relevant for the postsurgical period (lack of oedema, pain, necrosis) and treatment outcome. For these reasons, the LiteTouch™ Er:YAG laser is a preferred tool in oral soft tissue surgery for

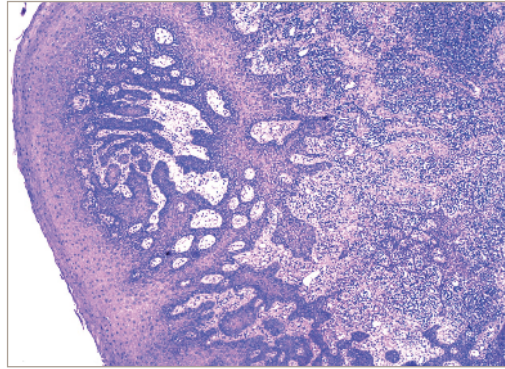


Fig. 15 Histopathological view of the excised specimen shows stratified squamous epithelium with proliferating rete ridges; connective tissue showing abundant plump and proliferating fibroblasts that are spindle shaped forming a network. Few endothelial lined blood vessels are also observed (H&E, 60x).

different procedures such as gingivectomy, frenectomy, operculectomy, incisions, etc.²²

In the presented cases, the gingival overgrowth was treated satisfactorily via initial periodontal therapy including oral hygiene instructions, followed by surgical gingivectomy with LiteTouch™ Er:YAG laser. This case report also demonstrates that without a change in associated drug, a proper periodontal treatment using laser can yield a satisfactory clinical response. However, there is a possibility for the gingival hyperplasia to recur as long as the associated medication is continued and in persistence with other risk factors.²⁴

There are a few studies on recurrence rates after a scalpel gingivectomy, but in this case report, patients' follow-up after twelve months showed no signs of recurrence.

Conclusion

Our case report confirms the effectiveness of the LiteTouch™ Er:YAG laser use for gingivectomy of drug-induced gingival hyperplasia. The treatment was well accepted by the patients, who had no pain and discomfort both during and after the procedure. However, inspection and further assessment of patients are mandatory to avoid relapse.

Editorial note: A list of references is available from the publisher.

contact

laser

Dr Blagovesta Yaneva

DDS

3 Hristo Botev Blvd., 4000 Plovdiv, Bulgaria

Department of Periodontology and oral diseases,

Faculty of Dental Medicine, Medical University-
Plovdiv

Tel.: +359 888 53 95 88

b_yaneva@yahoo.com